

# CASE STUDY: Ozan Gutierrez - 4 years old

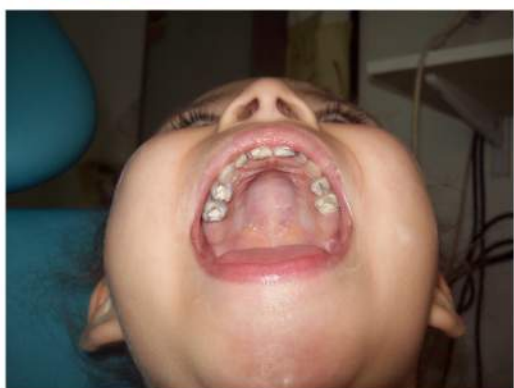
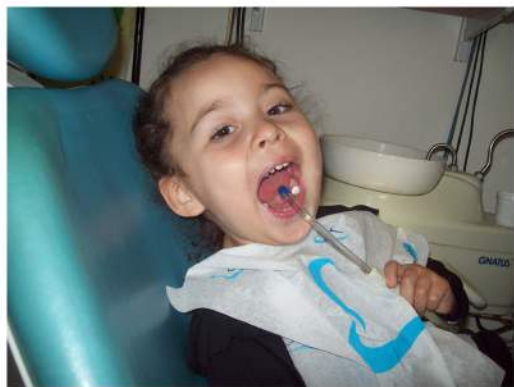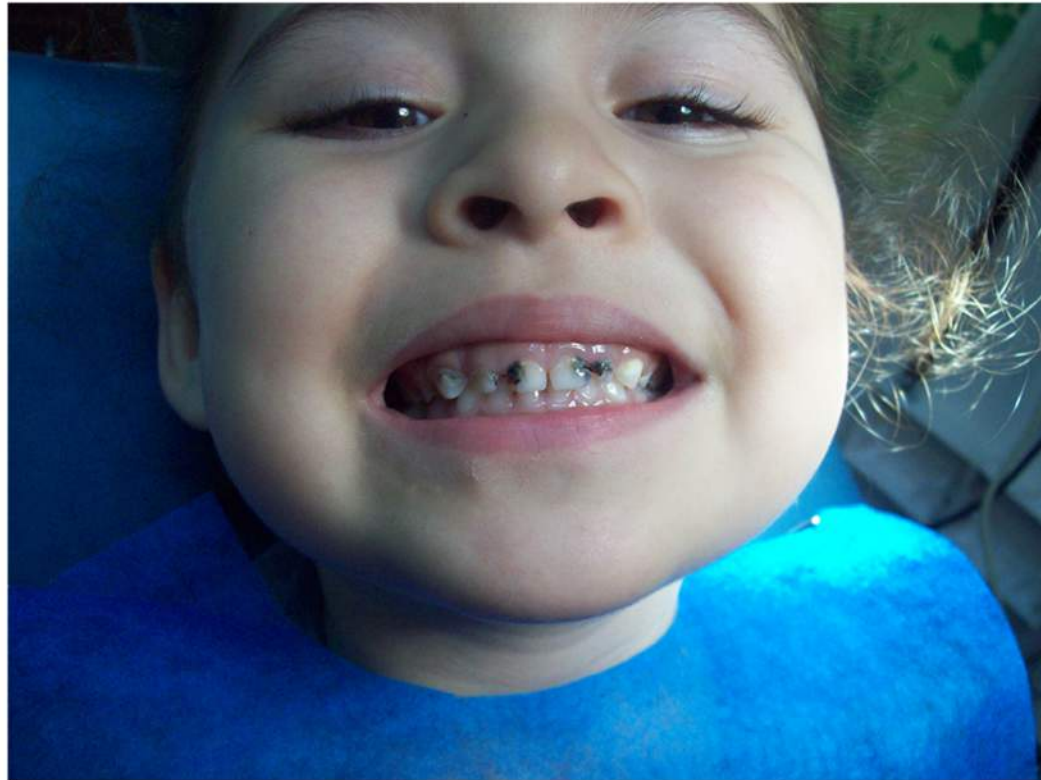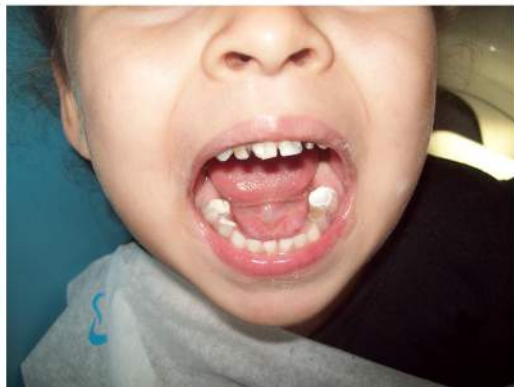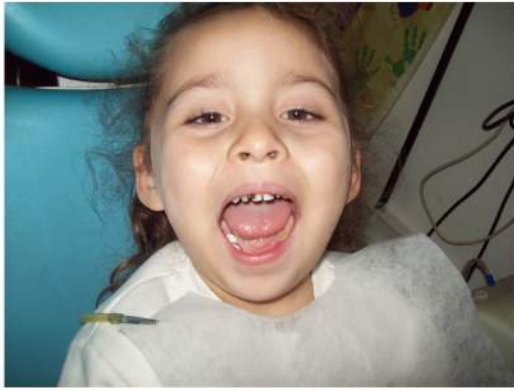
November 2015



First Treatment: 09/04/2015

Last Treatment: 08/11/2015

11 appointments



Ozan was diagnosed with 13 cavities on the 9th April 2015. This was caused by baby bottle tooth decay (also called early childhood caries, nursing caries, and nursing bottle syndrome) which happens when a baby's teeth are in frequent contact with sugars in their drinks. Ozan's mother added sugar to the milk bottle to speed up the weaning process. Toddlers in the slums are often sucking on bottles of sweet drinks to stop them from crying.

Attending Sonrisa III, Rodrigo, our dentist treated two of Ozan's cavities as root canals. Root canals are performed on young children rather than extractions, in order to 'save the space'. If milk teeth are lost before the permanent teeth grow, the nearby teeth can tip or shift, resulting in not enough room for the new teeth.

Despite living far away, she never missed an appointment and has been taught how to brush her teeth regularly and how bad sugary drinks are for her beautiful new teeth, now and in the future